

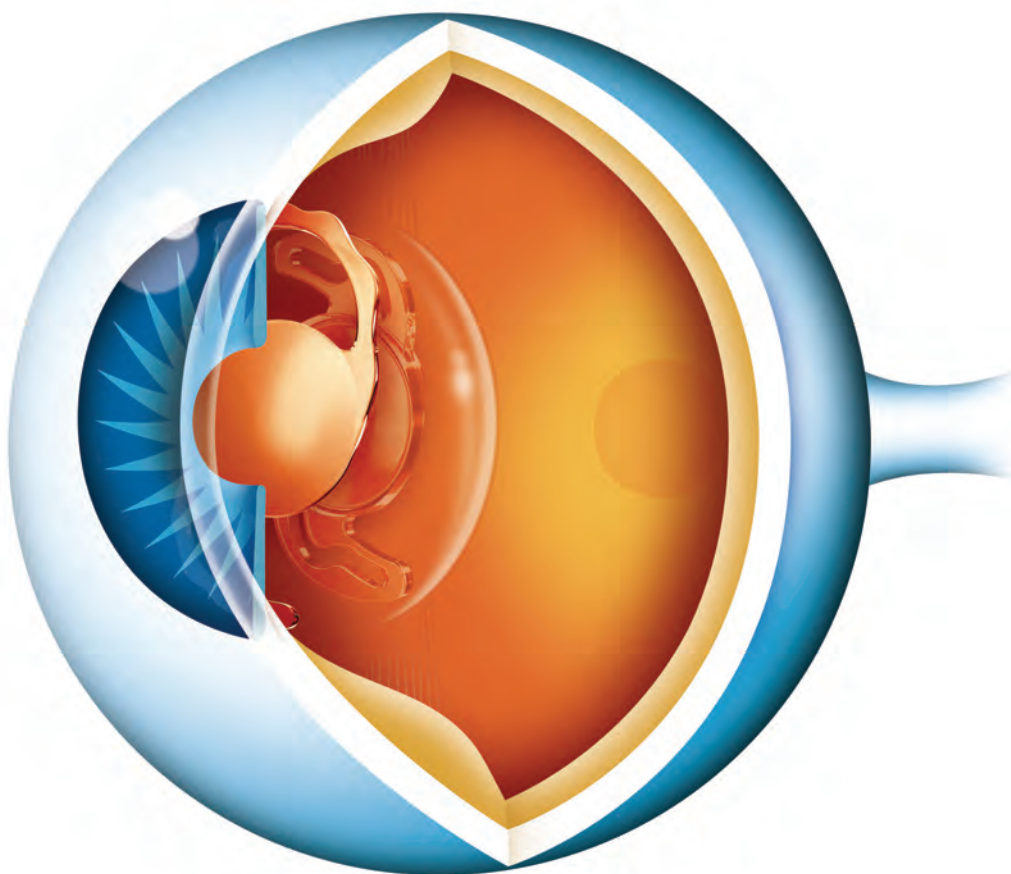
Supplement to

# Cataract & Refractive Surgery

**EUROPE**

**TODAY**

November/December 2009



## **Sulcoflex<sup>®</sup> Pseudophakic Supplementary IOLs**

Roundtable discussion featuring comments from Charles Clauoué, MA, MD, DO, FRCS, FRCOphth, FEBO, MAE;  
Michael Amon, MD; Robert Daniel, BSc, MBBCh, DA(S), DIP, PEC(Sa), FCOphth(SA);  
Norbert Körber, FEBO; and Richard Smith, MD

Sponsored by an unrestricted educational grant from Rayner Intraocular Lenses Limited

# Sulcoflex® Pseudophakic Supplementary IOLs

## MODERATOR:



**Charles Clauoué, MA, MD, DO, FRCS, FRCOphth, FEBO, MAE**, is a Consultant Ophthalmologist at Queen's Hospital, London, Barking Havering and Redbridge University Hospitals NHS Trust, and in private practice in London. Mr. Clauoué states that he is a consultant to Rayner Intraocular Lenses Limited. He may be reached at tel: +44 20 88 52 85 22; e-mail: eyes@dbcg.co.uk.

## PARTICIPANTS:



**Michael Amon, MD**, is a Professor and Head of the Department of Ophthalmology, Academic Teaching Hospital of St. John, Vienna, Austria. Dr. Amon is the inventor of the Sulcoflex®. He may be reached at tel: +43 406 99 97; e-mail: amon@augenchirurg.com.



**Norbert Körber, FEBO**, is in private practice in Cologne, Germany. Dr. Körber states that he has no financial interest in the products or companies mentioned. He may be reached at tel: +49 2203 10 19 70; fax: +49 2203 10 19 729; e-mail: n.koerber@gmx.de.



**Robert Daniel, BSc, MBBCh, DA(S), DIP, PEC(Sa), FCOphth(SA)**, is in private practice at Morningside Medi-Clinic, Linmeyer, South Africa. Dr. Daniel states that he has no financial interest in the products or companies mentioned. He may be reached at tel: +11 884 5624; fax: +11 783 7649; e-mail: robdaniel@doctors.org.uk.



**Richard Smith, MD**, is in private practice in Sydney, Australia. Dr. Smith states that he has received financial support from Rayner Intraocular Lenses Limited to attend and present his clinical results at an international congress. He may be reached at e-mail: richardsmith@eyemax.com.au.

Cataract surgical outcomes today achieve excellent refractive results in many cases; however, when a multifocal or toric enhancement is desired, or when residual refractive errors do occur, supplementary IOLs are a viable option for correction. The Sulcoflex® (Rayner Intraocular Lenses Limited, East Sussex, United Kingdom; Figure 1) is designed to provide multifocality and/or correct postoperative or residual toric/sphere ametropia without the trauma or increased surgical risk associated with IOL exchange. When implanted, the unique IOL design ensures a safe distance between it and the primary implant (Figure 2), thus reducing induced refractive errors or aberrations. It also has design features to make it safe for sulcus placement.

Five surgeons convened in Barcelona, Spain, during the European Society of Cataract and Refractive Surgeons (ESCRS) meeting to discuss their clinical experience with the Sulcoflex®. This supplementary IOL is specifically indi-

cated for the correction of postoperative ametropia, enhancement after IOL exchange, enhancement of near or far vision, correction of residual corneal astigmatism, and correction of refractive changes after pediatric cataract surgery. Below is a transcript of the discussion on the concept, design, and considerations for use of the Sulcoflex®.

Clauoué: Thank you for joining me to discuss the Sulcoflex® supplementary IOL, which is composed of a proprietary hydrophilic acrylic copolymer that has excellent uveal biocompatibility. It may be a terrible secret, but Michael Amon, MD, invented the Sulcoflex®. He will share an introduction to this lens with us.

## CONCEPT AND DESIGN

**Amon:** Thank you, Charles. In the early 90s, surgeons began piggybacking IOLs as a primary implantation strat-



Figure 1. The Sulcoflex® is available in (A) monofocal aspheric, (B) multifocal, and (C) toric models. It has an optic body diameter of 6.5 mm, an overall length of 13.5 mm, and posterior haptic angulation of 10°. Its optic configuration is anterior convex, posterior concave.

egy to correct high hyperopia or myopia or as a secondary surgery when there was a biometric surprise. At that time, both IOLs were implanted into the capsular bag. This technique caused problems in a lot of cases, namely interlenticular opacification (ie, opacification as a result of lens epithelial cell ingrowth on the interface). Another problem was the contact noted between the central zones, which occurred when you implanted two biconvex lenses into the same space. Because of the contact between the IOLs, central flattening and a hyperopic defocus resulted.



The Sulcoflex® presents an exciting new option for enhancement of postsurgical results or primary duet implantation.

—Michael Amon, MD

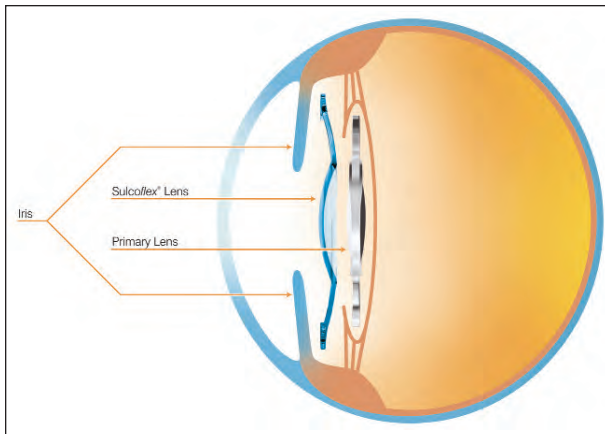
The Sulcoflex® is designed to avoid contact between the two optical zones. By creating a concave posterior surface with the second lens, the central zone of contact is avoidable, as is the hyperopic defocus. The second thing is that the supplementary IOL is implanted into the sulcus instead of the capsular bag, which avoids interlenticular opacification. If a refractive surprise occurs, use of the Sulcoflex® avoids the more

complicated lens exchange procedure.

As I started doing my first cases with the Sulcoflex®, I realized that versatility is important. It is not just an operation to correct ametropia—you can do it as an enhancement to provide the patient with an additional benefit or you can do it as part of the primary cataract operation in one setting. I call this procedure *duet implantation*. For instance, sometimes it is advisable to implant the Sulcoflex® during cataract surgery in cases of very high myopia or hyperopia. Other indications for duet Sulcoflex® implantation are presbyopic (multifocal Sulcoflex®, Figure 1B) and astigmatic (toric Sulcoflex®, Figure 1C) corrections.

In most cases, I implanted the Sulcoflex® secondarily. It is a concave lens with a concave posterior surface. The material is also important: It is a hydrophilic acrylic material, which is known for its high uveal biocompatibility. The IOL is 13.5 mm in diameter; its 6.5-mm optic has a round edge (to avoid dysphotopsia) because this lens does not need to protect the patient from posterior capsular opacification (PCO) and it is not positioned in the bag. The large haptics should provide good rotational stability and centration; the 10° angulation prevents the IOL from touching the iris, creates uveal clearance, and prevents pigment dispersion.

Rotational stability with the Sulcoflex® is very high. We have followed eyes for 2 years, and all are stable. It is a safe and easy surgery with less induced trauma compared with IOL exchange. Postoperative refraction is also stable, with good predictability. There have been no severe complications after 2 years. Iridotomy/iridectomy is optional, and I only perform it in eyes with a very small anterior



**Figure 2.** Illustration of the Sulcoflex® implanted in the sulcus, anterior to the primary IOL.

segment or in children. I have not seen an eye with angle-closure glaucoma.

It is a biocompatible, injectible, single-piece IOL, and it is a reversible procedure. I think the Sulcoflex® presents an exciting new option for enhancement of postsurgical results or primary duet implantation.

**Claoué:** Michael, you think that this will be an alternative to laser enhancements, and I would agree. Although all of us participating in the roundtable have easy access to refractive lasers, I think it is important for us to agree that most lens surgeons worldwide may not have equal access. A further important point is that the Sulcoflex® is an excellent, and much cheaper, alternative to laser adjustment of IOL power in the eye, such as the Calhoun Light Adjustable Lens system (Calhoun Vision, Inc., Pasadena, California). Norbert, would you be happy not to do a peripheral iridotomy (PI) if you implant the Sulcoflex®?

**Körber:** That is correct; I do not find it necessary to perform a PI. You, of course, have to clinically assess the patient. In cases with proper placement, it is not needed. However, to some patients, we may have the idea that the primary lens is positioned anteriorly, and then you may discuss iridotomy.

**Smith:** I do not use PIs, either. The few that I have done were unnecessary.

**Daniel:** I did PIs in my first four cases, but after that I have stopped. I have not had a single problem with intraocular pressure.

**Claoué:** I believe that you must assess each patient

individually. If the anterior chamber is anything other than deep, I am very prone to do a laser PI. It is an easy procedure to do, with very low risk. But it is nice to hear that the group consensus is that you do not need to do a PI in all cases.

### **MATERIAL**

**Claoué:** We should talk about the material of the Sulcoflex®. This IOL is made of hydrophilic acrylic, the dominant material in the European Union; hydrophobic acrylic is dominant in many other markets. There are also silicone and PMMA materials still in use as well. I wonder, Michael, what made you choose hydrophilic acrylic?

**Amon:** It is known that hydrophilic acrylic has high uveal biocompatibility. Therefore, as this material comes into contact with uveal tissue in the case of sulcus placement, the body has to tolerate the IOL. So, you will not find a lot of foreign-body giant cells coming from the blood stream and sitting on this lens material. If you compare lens materials, which I have done in a number of studies, you find that the hydrophilic material has the best uveal biocompatibility. That is the reason why I chose this material.

**Claoué:** Thank you, Michael. An additional advantage of using hydrophilic acrylic is the pliability of this material. It is gentle and does not apply severe force to the tissue. Other materials that do exert severe force have the tendency to cause erosion. We also know that this material is clear and does not develop glistenings.

### **IOL EXCHANGE VERSUS SULCOFLEX®**

**Claoué:** Let us now explore Michael's comments about IOL exchange. Richard, what is your opinion on the safety of an IOL exchange more than a few months after the surgery?

**Smith:** I do everything I can to avoid IOL exchange because it can be a difficult operation. You run the risk of damaging a healthy eye. If it is a case of poor refractive outcome, I will do a laser enhancement.

**Claoué:** I think we have to differentiate between a lens exchange for optical reasons—in terms of a refractive outcome including a change from monofocal to multifocal—versus a lens exchange where the lens is malpositioned. We would agree that late lens exchange is prone to a poor outcome. It is less straightforward than secondary lens implantation.

**Amon:** Especially after Nd:YAG laser treatment.



I do everything I can to avoid IOL exchange because ... you run the risk of damaging a healthy eye.

—Richard Smith, MD

**Claoué:** And especially if a posterior capsulotomy has already been done. There is some question about implanting a secondary lens in the early postoperative phase; some surgeons would argue that it is easy to exchange the lens in the first few months.

**Amon:** It is easier to do it in the first week versus the first month. Nevertheless, as soon as you begin to perform capsular surgery, even in the best hands, you always run the risk of losing some tissue and opening the capsule. In other words, you are at risk for complications and touching the vitreous. For that reason, I think even in the cases when it is easy to perform the lens exchange, it nevertheless is safer and easier to perform a second implantation.

**Claoué:** I agree with you entirely. I would just like to explore the group's view on a different early refractive surprise, and that is when the manufacturer you use mislabels the refractive power. Now, if the lens you originally implanted was not the power that you expected, and you back calculate to put in a new lens, you will get a second refractive surprise. Obviously that is bad for the patient as well as your practice. The great attraction of the Sulcoflex® is that it does not matter what the first lens power is. Indeed, you do not need to know it. It requires only a simple vertex measurement and the refraction. So, it is an immensely safe procedure in terms of predicting refractive outcome. I think that aspect of refractive lens exchange for a refractive surprise is perhaps underestimated in the literature.

I can see that people who look at this product would say they never need to enhance patients. I wonder whether there are populations who will be ready for cataract surgery in the near future where refractive results will be less predictable.

**Daniel:** I have done a number of cases that were either previous radial keratotomy (RK) or laser vision correction patients. Once that first procedure is done, there is a very high hit rate on a plano refraction with the Sulcoflex®. You get a degree of safety and can almost guarantee that the patient will be within  $\pm 0.25$  D at the end of it. That is what really gives you the security.

**Claoué:** Very true. This large cohort of postrefractive surgery patients are marching toward cataract surgery in a few years, all of whom have high expectations—much higher than the patients we are used to. They expect excellent visual acuity and yet are technically challenging in terms of their biometry.

I am unimpressed by the large number of available biometry options. The vast number of different recommendations tells me that none are perfect. My management style is to tell patients that they will have two procedures in order to achieve the optical outcome that they want. Nobody ever objects if they do not have that second procedure. But, the real risk is the patient who is expecting one procedure and needs two. This tool that Michael has given us has made my life much easier—these patients can now have the first IOL ever designed for piggyback use. It allows me to give patients their perfect optical outcome.



You get a degree of safety and can almost guarantee that the patient will be within  $\pm 0.25$  D at the end of it.

—Robert Daniel, BSc, MBBCh, DA(S), DIP, PEC(Sa), FCOphth(SA)

**Smith:** I absolutely agree. We are seeing a cohort of post-LASIK and post-RK patients coming through. In some of these patients, the cornea is no longer treatable by laser enhancement. There are limits to how much correction we can give them. It is important to counsel every patient about the possibility of a second procedure. The Sulcoflex® offers a great solution.

#### TORIC MODEL

**Claoué:** When the toric Sulcoflex® model is implanted, rotational stability is crucial. I have seen some toric designs with teeth on the haptics, and I have not had pleasant experiences rotating these into position. However, the gentle and smiling lips (called *undulations*) of the Sulcoflex® look much friendlier. But, I want to know how easy this lens is to dial in the eye and get the orientation of a toric lens perfect?

**Körber:** Well, the dialing is easy, especially compared with other designs. The lens is very gentle to move; if you fill the space nicely with a hyaluronate or other ophthalmic viscosurgical device (OVD), it is easy to accomplish.

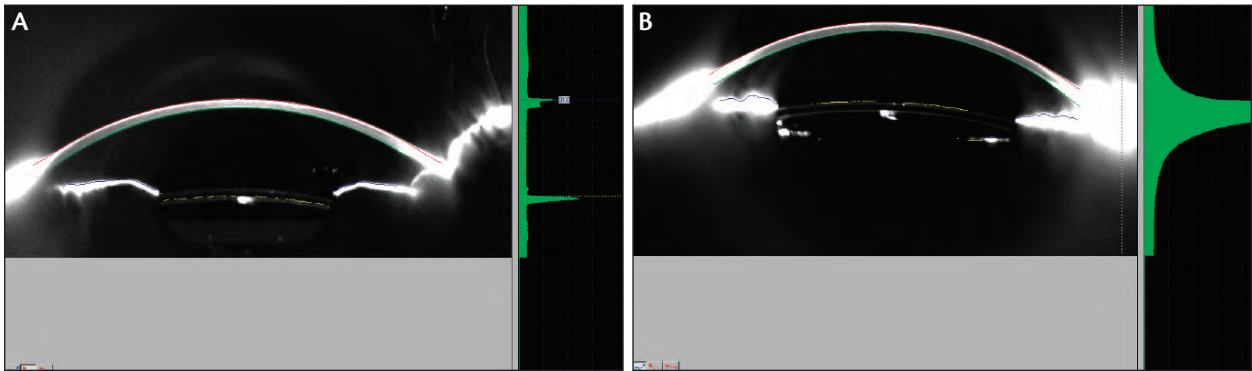


Figure 3. (A, B) Scheimpflug images confirm a good separation of Sulcoflex from the primary implant and also excellent alignment of the two lenses.

**Claoué:** Do you think removing the OVD is an important part of maintaining rotational stability?

**Smith:** Well, I think it is important to remove as much as you can; however, I do not think it is important in relation to stability. If one were to finish the case with the lens correctly aligned, it will stay there. I brought a case that demonstrates a good opening to our discussion on toric lenses.

This man was referred to me. He was 70 years old and had pellucid marginal degeneration (PMD) in his right eye. I noted 11.00 D of corneal astigmatism in his right eye and 18.00 D in his left. The bottom of his cornea was thin and bulging.

Chances were that his refraction was fairly stable at this stage, and I did cataract surgery using the highest available Rayner toric IOLs. The right eye received 4.00 D spherical correction and 11.00 D cylinder. The left eye yielded a final refraction of -5.75 2.00 X 15°. A Sulcoflex® 6.50/+4.0 brought unaided vision to 6/5. This case was the first time I used the Sulcoflex®. It produced a stunning result in a really extreme case.

**Claoué:** I have to say, looking at your figures, stunning is just not an adequate word. I think as few as 5 years ago, none of us would believe that that sort of optical outcome was possible.

**Smith:** It is just wonderful. When the cornea is untouchable, this option is fantastic. I am a big proponent of toric lenses and use them any time there is more than 0.75 D of definite corneal cylinder. This represents approximately 50% of cases.

We do Orbscan (Bausch & Lomb, Rochester, New York) and IOLMaster (Carl Zeiss Meditec, Jena, Germany) in all cataract and refractive lensectomy patients. You detect a percentage of corneas preopera-

tively that would be untreatable by laser adjustments postoperatively. Many patients today know that enhancements are available, and now we have another option to present them. We also have the generation that had cataract surgery before toric IOLs were available. Some have substantial astigmatism, which we can now address with the toric Sulcoflex® option.

**Claoué:** It is a wonderful case. I would like to encourage you further, Richard. Your main experience is with the toric model. Have you any experience of putting them in as secondary implants in patients who have had surgery more than 10 years ago?

**Smith:** No, but I see that as a valuable potential use.

**Daniel:** I have implanted four toric Sulcoflex® lenses to date. It provides very good visual outcomes. I would like to add a few words about my technique: I orient the lens to a reasonable accuracy and then wash out the OVD and do the final orientation. I do this in front and behind the optic because it just feels too unstable with the OVD. I feel more comfortable that I have cleared any debris from the interlenticular space. I make sure the IOL orientation is 100% before I come out of the eye.

**Claoué:** My technique is to leave a coating of OVD anterior to the iris. I wash out the OVD from behind the lens and immediately in front of the lens. I leave the lens just slightly under-dialed and dial it to the final position once I have done that.

Rayner provides a picture of what the lens will look like in the eye. You just have to remember that it is facing the head. If you are operating from the top, turn it upside down. If you are operating from the side, put it on your side. I think the most honest surgeons who manipulate astigmatism would admit that it is frighteningly easy to

get it in the wrong meridian. Fortunately, with an IOL, you can redial it the next day. With LASIK, it is slightly more difficult to dial into position.

### HAPTIC ANGULATION

**Claoué:** Michael, you have suggested a 10° posterior angulation for the haptics. I wonder if you can tell us about your rationale.

**Amon:** It is important to maintain good distance between the anterior surface of the optic and the iris to reduce the risk of pigment dispersion, iris chafing, and optic capture if the lens is placed in the sulcus. By deciding on an angulation of 10°, you have a nice clearance from the iris. In our Pentacam (Oculus Optikgeräte GmbH, Wetzlar, Germany) studies, all cases showed a significant distance between the tissue and lens surface (Figure 3).

**Claoué:** Important point. We are aware that there has recently been an editorial in the *Journal of Cataract and Refractive Surgery* pointing out the problems of implanting lenses in the sulcus that were not designed to go in the sulcus.<sup>1</sup> There is a relatively high ocular morbidity associated with this.

You mentioned pupillary optic capture and suggest that the 10° posterior angulation of the haptics prevents it. Are there any other design features to this lens that make it unlikely?

**Amon:** Yes. The second is that the large optic (6.5 mm) lowers the risk of optic capture. Angulation and size of the optic preclude, I would say, optic capture.

**Claoué:** Some people are going to think that it is quite a large and bulky optic. Norbert, have you had any problems manipulating this lens or injecting it?

**Körber:** No, but I am also used to Rayner's Superflex®, which has the same optic. Compared with a 6-mm optic, 6.5 mm is not that much different—it's not that bulky. It is important to position the haptic correctly.

Coming back to the point of optic capture, I must say that many years ago, we already did secondary piggyback implants into the sulcus of high myopes, as we had many errors, especially after excimer treatments and also due to miscalculations after ultrasound biometry.

We used low-power, three-piece lenses in the sulcus and never saw any pupillary capture or optic capture. But, we must take care to remove the OVD behind the lens. Otherwise, there may be a little anterior displacement. This is optically, and maybe clinically, wrong.



We are aware [of] the problems of implanting lenses in the sulcus that were not designed to go in the sulcus.

—Charles Claoué, MA, MD, DO, FRCS, FRCOphth, FEBO, MAE

**Claoué:** Do you constrict the pupil on the table?

**Körber:** No.

**Daniel:** I do.

**Smith:** I do not. I might add that on the first case, I did tear a haptic. Fortunately, I had a back-up lens. I think for those who have not used this lens, you really have to be careful to tuck those long haptics neatly into the injector, a task I do under the microscope.

**Claoué:** As ophthalmologists, we are always pushing the manufacturers to improve these designs; what we want is a preloaded injector. I think that will resolve some of these issues.

I actually do constrict the pupil on the table with intracameral acetyl choline and pilocarpine to keep it constricted. Although optic capture has not been described, I think it is something that is best avoided. The 10° posterior angulation is great. Michael, you also mentioned iris chafing. Is there anything else in the design of this IOL that makes that less of a likely problem?

**Amon:** The edges of the optic are round, which not only avoids iris chafing but increases the safety. The round optic should reduce optical phenomena.

**Claoué:** This is an important feature, and it is wonderful that, in our obsession with square edges and IOLs, we have managed to remember that this is a platform where it would be a bad thing. This lens has been well designed.

Michael, you also mentioned problems with hot spots and dual focus when the two optics touch each other. How have you got around this problem with this new piggyback lens?

**Amon:** The posterior surface of this lens is concave, so it shouldn't contact the anterior surface of the first lens. In our Pentacam examinations, we could see that there was enough distance between the lenses across the entire area. If the patient had a flat first lens, the distance to the second lens was larger. But there was no case where we

found contact between the two IOL materials.

**Daniel:** I have also never seen any optic-to-optic contact with this lens.

**Körber:** I have a question. If the PCO is rather prominent with production of peripheral Elshnig's pearls, the peripheral anterior capsule of the lens will be prominent and may even displace the Sulcoflex®. Has that been observed, or is it too early to ask?

**Amon:** In my cases, I have not observed this. But if the distance between the two IOLs would change slightly, I do not think it would create a problem.

**Smith:** I think, too, it is rare these days to see pearl formation in front of the optic. I have seen it a lot behind the optic of the Akreos lenses (Bausch & Lomb) after they have had capsulotomies. Rayner's lenses tend not to.

**Claoué:** I think that was a problem in pre-capsulorhexis days. Now, more lenses have a 360° square-edge design on the front as well as the back.

### ASPHERIC BENEFITS?

**Claoué:** What does the concave posterior surface of the optics do to higher-order aberrations?

**Amon:** That is difficult to answer, but I will mention a note on asphericity. The lens is neutrally aspheric, meaning it does not induce any additional aspheric aberration. That is important because the first lens may already have some asphericity. So, it is important to have a neutral lens that does not correct the corneal asphericity if it is not needed. From the concave point of view, however, I cannot answer.

**Claoué:** These lenses are very low power, at least in terms of spherical error. And, low spherical lenses have very low spherical aberration. I am not quite convinced how important having an aspheric is. I am going to continually ask the manufacturers to customize aspheric corrections for individual eyes. To me, it is amazing that we accept a single variety of asphericity from manufacturers. However, because these are mainly low-powered lenses, I think that the degree of asphericity may actually not be that important.

**Smith:** I agree, asphericity is not that important. When you look at the enormous experience with nonaspheric IOLs and the excellent vision that they yield—and now that there are at least three levels of aspheric lenses on

the market—you struggle to perceive a difference in clinical outcomes. I know this notion of customization is available, but for the most part, I think it is relatively unimportant.

**Körber:** I am more or less on the same wavelength.

**Daniel:** I agree as well, there is no advantage.

**Amon:** Yes, me too. The question is for the depth of field. To tell the truth, I know the principle but I do not know what impact it has for the patient.

**Claoué:** We have been referring to our experience with patients, but we must also look at the evidence. Johansson's multicenter Swedish study confirmed patient appreciation for aspheric IOLs.<sup>2</sup> Half of patients enrolled in the study could not tell which eye had the high negative aberration lens and which had the zero aberration lens. These results either implied that reducing spherical aberration may not be important in most patients or that these lenses were not adequately customized to the patient to show an effect. In the remaining half of patients, twice as many preferred the zero aberration to the negative aberration lens. This study suggests that a standard negative spherical aberration lens is not a good idea. That has been supported by Denoyer,<sup>3</sup> who has shown that the high negative spherical aberration lens is better for night driving. However, for activities of daily vision, the zero spherical aberration lens is better.

I am demanding a customized lens, but I accept that in 2009 and 2010 the best IOL has zero spherical aberration.

**Smith:** I agree with you, and I do not use negative spherical aberration lenses. I think it is pushing that issue too far. In a way, we have only fairly recently arrived at the use of IOLs that tailor spherocylindrical refractive error.

**Claoué:** I agree. We still are exploring toric and toric multifocal IOLs. To some extent, it could be argued that we must explore these lenses first before we move on to higher-order aberrations. It would seem logical to correct Zernike 1 and 2 before we move to correct higher-order aberrations.

### MULTIFOCAL SULCOFLEX®

**Claoué:** Michael, please tell us about the different optics you would like to see or have seen on the Sulcoflex® platform.

**Amon:** We now have three options. A monofocal neutral aspheric lens; the toric version; and the multifocal

option, which is a refractive optic with an addition of 3.50 D. The multifocal Sulcoflex® has five optical zones with quite a small central zone. The function of the multifocal Sulcoflex® is not too dependent on pupil size.

I have implanted all designs secondarily; however, I have also performed duet implantation. In the latter, I operate on the cataract, implant the IOL in the bag, remove the OVD material from the bag, and then implant the Sulcoflex® in the same procedure.

**Claoué:** I have always believed that absolute presbyopia is the commonest complication of uncomplicated cataract surgery. It is so common that we forget about it. What we neglect is that two-thirds of patients request spectacle independence. In 100 years' time, ignoring presbyopia will be unthinkable. The problem is that to date, we don't have a perfect technology. On the one hand, we have accommodating IOLs that work at best to an unpredictable extent by physiological means that we don't understand fully. On the other hand, we have multifocal lenses whose optics and physiology we understand but have been subjected with unwanted side effects, such as halos.

My main experience has been with the M-flex® (Rayner Intraocular Lenses Limited) as a primary implant, which has a very low rate of halos. This, I believe, is due to the refractive index of the lens material. What I would like to know from you, Michael, is if your patients who receive a Sulcoflex® multifocal have had any unwanted visual affects.

**Amon:** Only one of my patients has halos; however, he is still very happy with the result. This patient said that the halos reduced over time. The other four patients have had no halos.

**Claoué:** Experienced surgeons know that most multifocal patients have a period of neuroadaptation, and that at 6 months, the halo issue is no longer a big problem. However, we also have patients who are not quite certain about whether they would like a multifocal lens. I see the multifocal Sulcoflex® as a way of implanting a supplementary IOL as a multifocal trial. If the patient cannot tolerate multifocality, the Sulcoflex® can be removed without attacking the capsular support.

**Daniel:** I have had to explant one Sulcoflex®. It was remarkably easy. Trauma caused by removing the lens is insignificant, particularly compared with the trauma of removing an in-the-bag monofocal, which happens with regularity. I think that it is a good opt-out for something that you are not sure the patient will accept.

**Claoué:** So, the two main arguments against multifocal lenses are that patients may have halos (that has been addressed by the design of the Sulcoflex®), and that some patients do not tolerate multifocality. I think these two major anxieties that surgeons have, which prevent them from using multifocal implants, have been to a large extent resolved by these developments with the Sulcoflex®. I hope this will mean that many other patients will be offered multifocality as a primary procedure.

**Körber:** Yes, but it is also a question of reimbursement in our area. For 90% of the patients we talk to about multifocality, it is the question of if they will not pay anything for the surgery or everything, including the surgical procedure. So, this is a double issue that we have to talk about. From the point of view of wearing glasses, I think most people would be happy to not wear glasses again. But, when there is no reimbursement, then many people are OK wearing reading glasses if that means they don't have to pay anything out of pocket. However, many patients who can afford to pay choose multifocality.

**Claoué:** *Eye*<sup>4</sup> and the *Journal of Cataract and Refractive Surgery*<sup>5</sup> have published some good papers this year on the cost advantages of multifocality. I think when we have digested this, we will have good arguments to present to patients on why they should invest in better surgery with premium IOLs.

**Smith:** We have a very refractive practice, but I do not use multifocals at all because I prefer monovision lenses (one eye plano, the other -1.50 D). The reason that I choose not to use multifocals is that when you encounter a patient who is really unhappy with them, the only solution is to take those lenses out. I have had to do it, and late IOL exchanges may be difficult. You can't afford a substantial complication. The risk of multifocals is just that to me: a substantial risk. The Sulcoflex® does offer a nice alternative.

**Claoué:** I think you are justified to use monovision. You have to admit, though, that some patients hate monovision. The Sulcoflex® might provide an excellent way of turning someone with monovision, who is unhappy with the disparity, into someone with a balanced optical outcome. You could even change them to multifocal optics.

**Smith:** We have a huge experience with monovision. We found that 50% of people do not use glasses at all. Another 48% have reading glasses but only use them occasionally; 2% still use near and distance correction.

We always counsel patients about the possibility of secondary adjustments, and usually they are little adjustments. But you do occasionally get people who decide they cannot live with monovision. In those patients, we reverse them to bilateral emmetropia. But with the Sulcoflex®, you don't carry that huge risk of having to explant the IOL from the bag.

**Claoué:** So, Michael, your product will be able to cure monovision, if I may put it that way.

**Amon:** In the past, I was very hesitant to use a multifocal IOL. But knowing that the Sulcoflex® procedure is reversible, I feel more comfortable. You still get some monovision patients, even when you select them precisely, who are not happy with their outcome. The Sulcoflex® can be an option for monovision. I have such a patient where I added the Sulcoflex® to create monovision. If the patient isn't happy, if there is no neuroadaptation, you simply remove the lens at any time.

### SPECIAL CONSIDERATIONS

**Claoué:** I would like to ask the group's opinion about patients without biometry readings, such as patients with penetrating eye trauma. You are likely to put a primary lens implant in, knowing that you are guessing the biometry. My experience is that these patients have suboptimal outcomes. I think the Sulcoflex® would allow an easy way to top up their refraction. Rob, you must see a good deal of trauma in South Africa. What do you think about this idea?

**Daniel:** Wherever we end up, if it is within  $\pm 5.00$  D, we can fix the residual refractive outcome with a high level of confidence.

**Smith:** Charles, I think another group that may benefit from this lens is corneal graft patients, some of whom have also had laser adjustments with LASIK or PRK. If they develop cataract, choice of IOL power is difficult. IOL formulas are inaccurate in these patients, who may have substantial astigmatism and may require repeat corneal graft in the future. What I end up choosing to do is use a spherical IOL with the knowledge that I can top up with the Sulcoflex®. If they later need a regrant, you can always do it by taking the Sulcoflex® out and later topping up again.

**Claoué:** What we are talking about are patients with changing refraction. Newer forms of lamellar corneal surgery may make that less of a problem. There is one other group of patients that do have an entirely predictable changing refraction, at least for the first 18 years. I am of course talking about pediatric cataract surgery.

There is often discussion about what should be planned in these patients, knowing that children with refractive errors equal amblyopia. The closer to useful visual acuity you can get these children in the first 5 years, the better your amblyopia treatment will be; however, refractive outcomes as an adult will be poor. I think this lens is a perfect tool for sorting out the pediatric cataract surgeon's dilemma, when the patient reaches the age of 18 years.

**Amon:** After 2 years' follow-up, I now feel comfortable using this lens in children. My youngest patient is 2 years old. In that case, I implanted the calculated prospective IOL power the child would need as an adult with an IOL in the bag and the Sulcoflex® on top. I made the child emmetropic. If there is the need, I can explant or exchange the lens when necessary.

**Claoué:** I think that we need to be quite sure that our pediatric colleagues know about the Sulcoflex®, because I think it will have a big effect on their practice in terms of their refractive strategy.

**Daniel:** I have done a 15-year-old. He is actually a post-trauma patient. He was operated on 3 years ago, at the age of 12 years. He refuses to wear glasses for his refractive error (3.00 D). It was an uncomplicated case to implant the Sulcoflex®. It is exactly the same procedure as what we do in our adult cases. The interesting thing is that after the Sulcoflex®, he has consistently improved his UCVA, which from day 1 was better than his BCVA preoperatively. I suspect he is just before the tail end of the amblyopic recovery. I have a really nice result with him.

### DIFFICULT CASES

**Claoué:** Does anyone want to talk about any particularly interesting or difficult cases?

**Amon:** I have a patient with a silicone-oil-filled eye. He is an old patient with recurrent vitreous bleeding; he previously underwent vitrectomy. I decided to keep the silicone oil in the eye, and he was pseudophakic already. So, he ended with 5.00 D. For that patient, I put the Sulcoflex® in, and now he has a 0.40 vision with his eye, and he is happy. I think this is also a nice indication. If we ever remove the silicone oil, we just remove the lens again. A second point is that on hydrophilic IOLs, silicone oil does not adhere as intensely as on silicone and hydrophobic IOLs.

**Daniel:** I have a number of patients who have minor

corneal abrasions and superficial stromal scarring. What I do is use the Sulcoflex® lens to purposefully over-minus them. Then, I do PRK to have complete control of the refractive outcome. At the same time, because the scar is central, I am doing a myopic ablation. I am not doing a phototherapeutic keratectomy where I don't have control.

**Smith:** Why don't you put the Sulcoflex® lens in first?

**Daniel:** That way I can do my PRK later and get them exactly plano for that optical system.

### FURTHER DEVELOPMENTS

**Claoué:** How could this idea of the Sulcoflex® in the pseudophakic eye be further developed or mastered?

**Körber:** I think at the moment, this is just the perfect design. The only original concern is that I thought the height of the haptic may be too tall, thus causing iris chafing. But data show that nothing happens. At the moment, I do not know how we would improve it. The size of the optic is perfect, and the position is stable with no rotational problems.

**Daniel:** I think there is a learning curve with the injector system. The haptics are long and it can be quite tricky to load into the injector. Perhaps a softer plunger would make it less likely to tear the trailing haptic. But, it is not a detracting factor for me using the lens. I think it is something that you just need to be aware of.

**Smith:** Is there any potential for some accommodative approach given that you have got two lenses in the eye? The Crystalens (Bausch & Lomb) and other lenses with slight haptic movement have not really been successful. But, here is a way of getting two optics into the eye that may allow this sort of two-optic performance. I am always considering answers to the accommodative question.

**Amon:** Perhaps, but I think because the concept of the multifocal lens works well and the design works with Rayner's C-flex® platform, I think the next step should be a combination of a multifocal and toric correction.

**Claoué:** I am sure that is correct. It has been, up until now, that corneal astigmatism is a major contraindication to patients receiving a multifocal lens. With Rayner's toric multifocals, that contraindication is gone.

I would like to finish with a question: Are you prepared to recall your happy patients for a toric Sulcoflex® or a multifocal Sulcoflex®?



I think at the moment, this is just the perfect design. The size of the optic is perfect, and the position is stable with no rotational problems.

—Norbert Körber, FEBO

**Smith:** I would certainly consider it. In people with significant residual refractive error, I already discuss the possibility of a secondary adjustment.

**Körber:** We also advertise it—carefully, of course. Every now and then, I consult a patient whose first eye was operated many years before, and we discuss the issue of multifocal IOLs. They want that option. I think this is when we can ask patients if they want the Sulcoflex®, because there are a number of patients who would be interested in it. I think we should, very cautiously, address that issue in the office.

**Daniel:** I need my patients to be happy. The only way I can make them happy is to get them as close to plano as possible. I think we could make a strong case, particularly with hyperopic refractive surprises, that these people are debilitated. It is not that they need a refractive correction to actually get them to see without their glasses. My feeling is that it does not matter how much work you do but it is how well you do it. This allows me to genuinely make patients happy.

**Claoué:** I think one of the things we need to ask is: What exactly is a happy patient? Human beings have a tremendous ability to be happy with almost anything. I think that it is up to us to show people what is available by educating them. Happy is not an absolute. There can be happier. I think your invention, Michael, gives us a great opportunity to increase human happiness. There are not many ophthalmologists who can say that. Congratulations. ■

1. Mamalis N. Sulcus placement of single-piece acrylic intraocular lenses. *J Cataract Refract Surg.* 2009;35(8):1327-1327.
2. Johansson B, Sundelin S, Wikberg-Matsson A, Unsbo P, Behndig A. Visual and optical performance of the Akreos Adapt Advanced optical and Tecnis intraocular lenses: Swedish multicenter study. *J Cataract Refract Surg.* 2007;33:1565-1572.
3. Denoyer A, Denoyer L, Halfon J, Majzoub S, et al. Comparative study of aspheric intraocular lenses with negative spherical aberration or no aberration. *J Cataract Refract Surg.* 2009;35:496-503.
4. Lafuma A, Berdeaux G. Modeling lifetime cost consequences of ReStor for presbyopia in four European countries. *Eye.* 2009;23:1072-1080.
5. Maxwell WA, et al. United States cost-benefit comparison of an apodized diffractive presbyopia correcting multifocal intraocular lens and a conventional monofocal lens. *J Cataract Refract Surg.* 2008;34:1855-1861.

**Cataract & Refractive Surgery**  
**EUROPE** **TODAY**